

Does ultrasound guidance add accuracy to continuous caudal-epidural catheter placements in neonates and infants?

Vrushali C. Ponde  | Vinit V. Bedekar  | Ankit P. Desai | Kiran A. Puranik

Children Anaesthesia Services & Surya
Children Hospital, Santacruz (West),
Mumbai, India

Correspondence

Dr Vrushali C. Ponde, Children Anaesthesia
Services & Surya Children Hospital,
Santacruz (West), Mumbai, India.
Email: vrushaliponde@yahoo.co.in

Section Editor: Adrian Bosenberg

Summary

Background: Caudo-lumbar and caudo-thoracic epidural anesthesia is an established technique that carries a low risk of dural puncture or spinal cord trauma in infants. Traditionally catheter advancement is based on external measurements. However, malpositioning of catheters are known to occur. We hypothesized that caudal-epidural catheters inserted under real-time ultrasound guidance may be more accurate than the accuracy of the measurements traditionally used for their placement.

Methods: We studied 25 patients, aged 2 days to 5 months, posted for abdominal or thoracic surgery, receiving general anesthesia followed by caudo-epidural continuous block. External measurement defined as the distance from the caudal space and the surgically congruent vertebral level was measured in centimeters with the back gently flexed. Subsequently, a caudo-epidural block was performed in the same position. The epidural catheter insertion was followed under real-time ultrasound guidance till the predetermined vertebral level was reached. The actual length placed under real-time ultrasound scan was defined as the actual length. The high-frequency probe was placed longitudinal and paramedian to the spine. The vertebral level was determined by identifying the lumbosacral junction in longitudinal sagittal view and counting the vertebrae up from L5. The catheter length at the skin was compared with the length recorded by external measurement.

Results: The actual length placed under real-time ultrasound scan were consistently longer than the external distance between the caudal space and selected vertebral level. The mean values of ultrasound were higher than the mean values of external measurement with a difference of 4.28 cm. Accuracy was not affected by age or affected by the selected vertebral level in the age group we studied.

Conclusions: We conclude that catheters placed under ultrasound guidance are more accurate than the traditional method developed before the advent of ultrasound in young infants.

KEYWORDS

accuracy, epidural catheters, infants, neonates, ultrasonography

1 | INTRODUCTION

In neonates and infants, caudo-lumbar and caudo-thoracic anesthesia is an established technique. It carries a smaller risk of dural puncture or spinal cord trauma than a direct thoracic or lumbar epidural approach.¹ The clinical efficacy of this technique is best if the location of the catheter tip is congruent with the vertebral level of the surgical incision. Usually the length of the caudal-epidural catheter required is determined by the distance between the caudal space and the surgically congruent vertebral level.² However, malpositioning is also known to occur with this technique.³

The position of the catheter tip can be confirmed using various techniques. These include epidurography, ultrasound, and nerve stimulation. For neonates and infants under 5 months, ultrasonography is reliable. Direct visualization of the spinal cord in this age group is possible as the vertebral column has not yet ossified and remains largely cartilaginous.⁴⁻⁶

Thus, we should be able to see the catheter entry into the caudal-epidural space and the route it takes as it is advanced cranially through this space using ultrasound guidance.

Our main objective was to determine whether the caudal catheter length inserted under ultrasound guidance was more accurate than those obtained with traditional method in neonates and small infants. We hypothesize that determining the insertion length of caudally inserted epidural catheters using US guidance will more accurately place the catheter tip at the desired vertebral level when compared to measurements derived from landmark-based external markings.

The secondary objectives were to determine whether there was any correlation of accuracy of external measurements, (confirmed with ultrasound guidance) with age and target vertebral level:

1. Correlation of accuracy of external measurements with age of the patient: We hypothesized that lesser the age, smaller the distance required for the catheters to travel in the epidural space to reach the target vertebral level, consequently more chances of the external measurements for placement to be accurate.
2. Correlation of accuracy of external measurements with target vertebral level: We hypothesized that external measurements to be accurate if the caudal catheters were to reach the lumbar vertebral level (closer target vertebral level) than the thoracic level (target vertebral level further away)

2 | MATERIALS AND METHODS

After IRB approval and informed written consent, 25 consecutive patients aged 2 days to 5 months, scheduled for abdominal or thoracic surgeries were recruited for this study. This was a prospective pilot study. Neonates and infants with congenital heart disease, coagulopathies, severe renal, hepatic, or neurological disorders were excluded. The patient's gender, age, and weight were recorded. After

What is already known

- Traditionally, caudal-epidural catheters are placed using external measurements for successful perioperative pain management in neonates and infants.

What this article adds

- Caudal-epidural catheters inserted under real-time ultrasound guidance were found to be more accurately placed as compared external measurements. Accuracy is not affected by age or the selected vertebral level in the age group we studied.

induction of general anesthesia with sevoflurane or propofol 2-3 mg/kg and atracurium 0.6 mg/kg, the patients were intubated with an appropriate size endotracheal tube. Caudal-epidural catheters were then inserted. Standard monitoring included electrocardiogram, pulse oximetry, noninvasive arterial blood pressure, capnography, and endtidal concentrations of volatile anesthetics.

To test our hypothesis, the surgically congruent vertebral level was marked. The distance between sacral hiatus and the respective vertebral level was measured in centimeters with the back in gentle flexion. This was noted as EM—Traditional external measurements.

Secondly, length of the catheter at the skin after visualizing the catheter tip reach the selected vertebral level in real time was noted as UM—Ultrasound measurement.

The statistical difference between the two readings and its significance was derived.

2.1 | Block Procedure

Continuous caudal-epidural block was placed with the patient in left lateral knee chest position, ie, with gentle flexion at the hip and knee maintained throughout the procedure. The patient position was unchanged from when external measurement was taken and epidural block was performed.

The vertebral level was assessed using ultrasonography. The vertebral level was determined using the following protocol. The lumbosacral junction was identified in longitudinal sagittal view. The vertebrae cephalad were counted up from L5.

The distance between the sacral hiatus and the surgically congruent vertebral level (EM) was measured in centimeters. An experienced anesthesiologist performed the continuous caudal-epidural block with a 19 or 18 gauge Touhy needle with their respective non-styleted (Smiths Medical India Pvt Ltd) catheter. A second anesthesiologist experienced in ultrasonography traced and followed the needle entry into the caudal space and the catheter advancement thereafter till the catheter reached the selected vertebral level. A high-frequency probe, 7 to 13 MHz (Micromax®, Sonosite Inc., Bothell, WA) was used. The ultrasound probe was positioned longi-

tudinal and paramedian to the spine with a slight inward tilt to obtain optimal ultrasound view. Bolus of 0.5 ml normal saline was given if resistance was felt during the advancement of the catheter in an attempt to reposition the catheter as previously described.

The following aspects were noted:

1. Visualization of the needle in the caudal space and the catheter emerging from its tip into the caudal-epidural space.
2. Ease of catheter insertion and the need to administer a normal saline flush.
3. The course taken by the epidural catheter.
4. Visibility of the tip of epidural catheter at the selected vertebral level.
5. Visibility of the local anesthetic spread in the epidural space at the selected vertebral level if catheter tip was not clearly visualized
6. Length of the catheter at the skin after placing the catheter tip at the selected vertebral level.

Drug spread at the desired vertebral level was accepted as the level when the catheter tip could not be seen. All patients received 0.5 mL/kg of 0.25% bupivacaine after securing the catheter. The catheters were tunneled subcutaneously and secured with a sterile dressing. A 20% increase in heart rate and blood pressure from baseline after skin incision was considered as inadequate analgesia. Fentanyl 2 mcg/kg IV was used as a rescue analgesic.

The postoperative pain regimen was as follows:

Pain assessment was performed using the CRIES scale in the NICU and PICU for 48 hours.

Analgesia was supplemented with paracetamol suppository 10-15 mg/kg 6 to 8 hourly.

Intermittent epidural boluses of 0.125% 0.5 mL/kg bupivacaine were given every 4 to 6 hours by the anesthesiologist on duty.

2.2 | Statistical analysis

The data were analyzed statistically using SPSS 20 software. All data are presented as mean±SD.

The EM and UM were measured and compared for statistical significance using paired *t* test. A *P* value <.001 was considered as significant. The correlation of age, vertebral level, external (EM), and ultrasound measurement (UM) was done using Spearman correlation.

3 | RESULTS

There were a total of 9 females and 16 males included in the study. The mean, standard deviation, and 95% confidence interval of age, external measurement (EM), and ultrasound measurement (UM) are shown in Table 1 and their differences are shown in Table 2. Table 3 shows correlation of age, vertebral levels, external, and ultrasound measurement.

The following observations were made.

The Touhy needle was visualized in the caudal space in all patients.

The catheter entry into the sacral hiatus from the needle tip was also appreciated in all patients (Figure 1A).

In 23 of the 25 patients, the catheter could be cranially advanced without resistance. In two cases, the advancement was smooth after a 0.5 mL saline bolus. Of these two cases, in one the advancement was easy, but neither tip nor any coiling of catheter could be visualized. In 12 of 25 patients, catheters were observed to slide in anterior epidural space from the posterior epidural space on their way to the selected vertebral level (Figure 1B and C).

In 22 of 25 cases, tip of epidural catheter was visible at the selected vertebral level. Drug spread was visualized in all 25 cases. No rescue analgesia in the form of additional fentanyl was required intraoperatively.

The mean values of UM were higher than the mean values of EM with a difference of 4.28 cm. This was statistically significant with a *P* value of <.001. There was no response to surgical stimulation in any of the patients.

The correlation of age with vertebral levels and EM were 0.23 and 0.31, respectively, which was not statistically significant.

The correlation with UM was statistically significant, *P* value <.001 (Table 3).

4 | DISCUSSION

The results of our study suggest that we could be more accurate with real-time ultrasound guidance in the age group we studied. It was also noted that the actual length placed under real-time ultrasound scan were consistently longer than the external distance between the caudal space and selected vertebral level. This could be explained by our observations while following the catheter route in the epidural space using real-time ultrasonography. We observed

TABLE 1 Descriptive table of age in days, EM, UM, and difference

Descriptive Statistics	Mean	Std. Deviation	N	95% CI	
				Lower Limit	Upper Limit
Age in days	33.72	49.595	25	-65.47	132.91
External measurement (EM)	12.16	1.405	25	9.35	14.97
Ultrasound measurement (UM)	16.44	3.652	25	9.136	23.744
Difference	4.4	3.253	25	-2.106	10.906

EM, external measurement; UM, ultrasound measurement.

TABLE 2 Paired t test to compare the external (EM) and the ultrasound measurements (UM)

Parameter	N	Mean	Standard Deviation	95% CI		PAIRED differences		95% CI of differences		t value	P value
				Lower limit	Upper limit	Mean difference	Standard deviation	Lower limit	Upper limit		
External measurement	25	12.16	1.405	9.35	14.97	-4.28	3.323	-10.926	2.366	-6.44	<.001
Ultrasound measurement	25	16.44	3.652	9.136	23.744						

CI, confidence interval; n, number of patients; t, test value.

TABLE 3 Correlation of age and vertebral levels, external, and ultrasound measurement

Correlations	
	Age in days
Spearman's rho	
Vertebral levels	
Correlation coefficient	.248
P value	.231
N	25
External measurement (EM)	
Correlation coefficient	.211
P value	.310
N	25
Ultrasound measurement (UM)	
Correlation coefficient	.665
P value	<.001
N	25
Difference between UM and EM	
Correlation coefficient	.596
P value	.002
N	25

Bold indicates P value <0.05 is considered significant. Ultrasound measurement and difference between EM and UM are significant.

that the advancing catheter does not follow a linear predicted path in the epidural space as expected. They were, in certain cases, observed to move freely from the posterior epidural space to the anterior epidural space before it reached the required vertebral level. This is shown in Figure 1B and C. Although the sensory tracts are all posterior, this does not seem to have affected the analgesia rendered. The chances of the catheter to travel in the anterior epidural space increase if a longer length of the needle is inserted into the caudal space. Either way the catheters can move to the other side of the epidural space.

It is logically appealing to assume that the lesser the distance a catheter is expected to travel in the epidural space, lesser is its chance to migrate, coil, or take any unwanted route. However, results of this study did not find any such positive correlation and refutes our secondary hypothesis. This perhaps indicated that catheters passed from the caudal to lower lumbar levels seem to have an equal chance of missing the selected vertebral level as the caudo-thoracic catheters. Secondly, this study also suggests

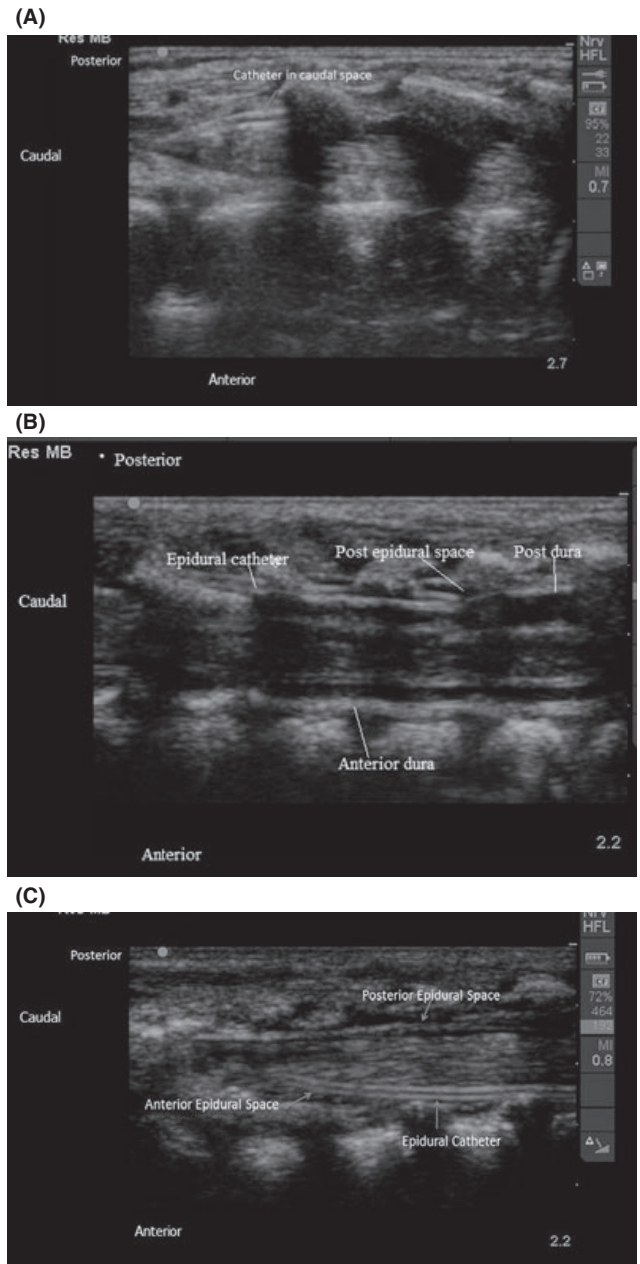


FIGURE 1 (A) Epidural catheter seen in the caudal space. (B) Epidural catheter as seen in posterior epidural space. (C) Epidural catheter seen in anterior epidural space

that there does not seem to be any correlation between age group (from day 2 to 5 months) studied and the expected difference in measurement of EM and UM (ie, accuracy of the external

measurements). This implies that the probability of the catheter being more accurate in a day old is similar to that in a 5-month-old infant.

On two occasions, the catheter advancement required additional saline flush. Of these two cases, in one case, we could not visualize the catheter tip and failed to show any advancement of the catheter in spite of a substantial amount of catheter insertion into the epidural space. In this case, we left the catheter at 12 cm at the skin. The propensity for coiling at the lumbar lordosis curve may explain this case. This was a 5-month-old baby for laparotomy and did not receive adequate pain relief perioperatively. The drug spread in this case was seen in the epidural space at L1 and beyond and may have covered the required segment for us to have achieved the analgesia. We did not do the fluoroscopic confirmation in this case because clinically it seemed to have worked.

Blanco et al⁷ studied success and degree of difficulty in placing in lumbar-to-thoracic advancement. In this study, the tip was located with fluoroscopy and was done in patients of around 41 months of age. The reported success rate was 52%.⁷ In our study, we used ultrasonography to locate the tip, avoiding radiation, and dye in this population. The use of ultrasound to assess the catheter position in three patients aged between 1 and 10 months was demonstrated by Roberts et al. The authors in these cases located the catheter and the tip after prior placement of the catheter with external measurements. We studied this in a bigger case series and compared it with traditional measurements to assess the accuracy of the external measurements.

In the study done by Chawate et al⁵ in children less than 6 months of age, a group similar to this study, the catheters were introduced via the lumbar region unlike our study. Children were scanned within 24 hours of epidural insertion by consultant pediatric radiologists. If the catheter was identified in the epidural space then an attempt was made to visualize the entire length of the catheter. They concluded that it was possible to visualize the epidural catheter in this age group. We used real-time ultrasound to place the tip accurately.

An important aspect of the use of ultrasound for the measurement is that this does not require radiation like fluoroscopy or an epidurogram, a significant advantage in this vulnerable population. The use of ultrasound may decrease the potential for trauma to the spinal cord.

The limitation of the study is the number of patients. A larger number of patients could be included for better results.

Further studies looking at dosing as a function of accurate tip localization along with accurate placement of catheter tip at the selected vertebral level should more clearly confirm the accuracy.

In conclusion, real-time ultrasound guidance increases the accuracy of tip placement in caudally threaded lumbar and thoracic epidural catheters when compared to use of landmark-based measurements alone. This accuracy was not affected by patient age or distance of the vertebral level from the sacral hiatus.

ACKNOWLEDGMENT

We acknowledge Dr. Adrian Bosenberg for preparation of this manuscript.

CONFLICT OF INTEREST

The authors report no conflict of interest.

ETHICAL APPROVAL

Institutional ethical committee approval obtained.

REFERENCES

1. Bosenberg AT, Bland BA, Schulte-Steinberg O. Thoracic epidural anesthesia via caudal route in infants. *Anesthesiology*. 1988;69:265-269.
2. Shah N, Lalwani K, Upadhyay M, Swadia V. Continuous caudal block: role in paediatrics. *Indian J Anaesth*. 2003;47:120-121.
3. Gunter JB, Eng C. Thoracic epidural anesthesia via the caudal approach in children. *Anesthesiology*. 1992;76:935-938.
4. Roberts SA, Galvez I. Ultrasound assessment of caudal catheter position in infants. *Pediatr Anesth* 2005;15:429-432.
5. Chawate MS, Jones RM, Gildersleve CD, Harrison SK, Morris SJ, Eickmann C. Detection of epidural catheters with ultrasound in children. *Paediatr Anaesth*. 2003;13:681-684.
6. Marhofer P, Greher M, Kapral S. Ultrasound guidance in regional anesthesia. *Br J Anaesth*. 2005;94:7-17.
7. Blanco D, Llamazares J, Martinez-Mora J, Vidal F. Thoracic epidural anaesthesia by the Caudal route in paediatric anaesthesia: age is a limiting factor. *Rev Esp Anest Reanim*. 1994;41:197-199.

How to cite this article: Ponde VC, Bedekar VV, Desai AP, Puranik KA. Does ultrasound guidance add accuracy to continuous caudal-epidural catheter placements in neonates and infants?. *Pediatr Anesth*. 2017;00:1-5.
<https://doi.org/10.1111/pan.13212>